

## INTRODUCTION

According to the International Association of Dental Traumatology (IADT) classification, complicated crown-root fractures **involve the enamel, dentine, cementum and pulp**. Such fractures account for approximately 5% of all dental trauma in the permanent dentition. Root fractures are also defined as fractures affecting **dentine, cementum and pulp** and are characterized by a complex healing pattern owing to concomitant damage to the various tissues. Dental trauma resulting root fracture is a rare condition that affects up to 7% of permanent teeth.

## Case Report

An 11 y/o AA boy was referred to our clinic after a fall on the sidewalk pavement resulting trauma to the anterior maxilla. He reported with splinted teeth 6-11 after suffering a complicated crown fracture on tooth #8 and horizontal root fracture on tooth #9.

### Medical History

- Non-contributory, no medications, NKDA

### Social History

- Lives in the US with Mom

### Dental History

- Last dental visit was > 6 months ago with a pediatric dentist in Brooklyn Ny. Mom states there were no significant findings

### Clinical Examination

- #8 Complicated crown fracture with fistula, #9 Horizontal root fracture

### Radiographic Examination

- #9 Horizontal Root Fracture, #8 Sinus tract with Gutta Percha

### Diagnosis

#8 Necrotic Tooth, #9

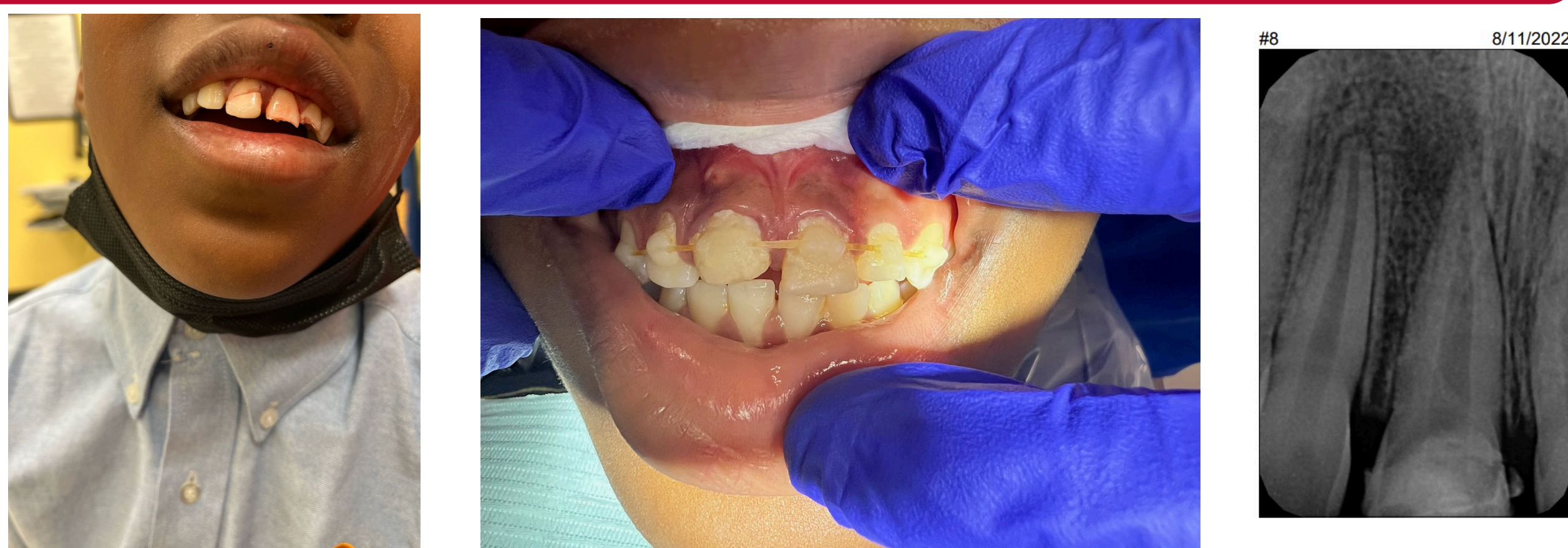
## Case Presentation

Patient presented to clinic with splinted teeth 6-11 after suffering a complicated crown fracture on tooth #8 and horizontal root fracture on tooth #9

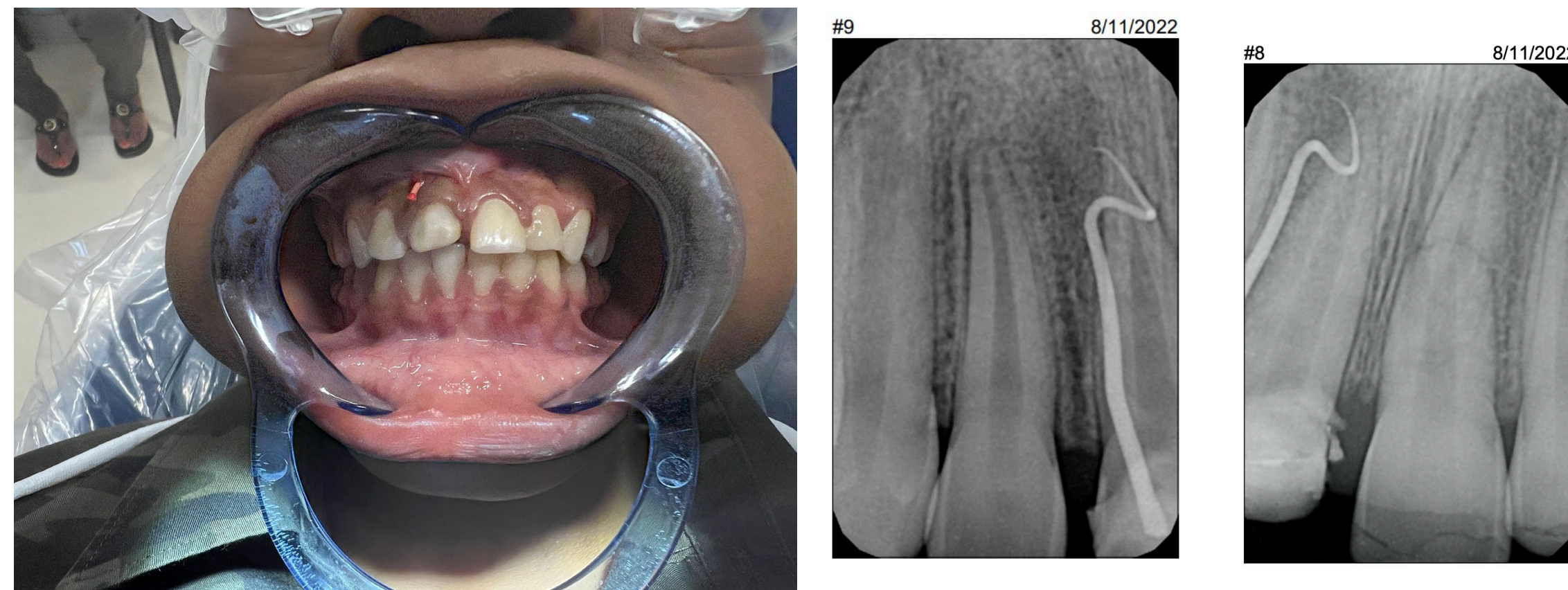
Under local anesthesia, Fistula was traced using gutta percha followed by an anterior PA and intraoral picture. (figure 2) Palpation, Percussion and Endo Ice test was completed on anterior teeth.

Teeth 7 – 11 responded negative (-) to palpation , Teeth 8 – 11 responded positive (+) to Percussion and #7 responded negative (-), teeth 7,9,10,11 responded 2-5 sec with Endo test and #8 was unresponsive.

## Figure 1



## Figure 2



## Case Management

### • First tx visit

Emergency exam, Pulp vitality test, Panoramic radiograph, Sinus tract traced with Gutta percha

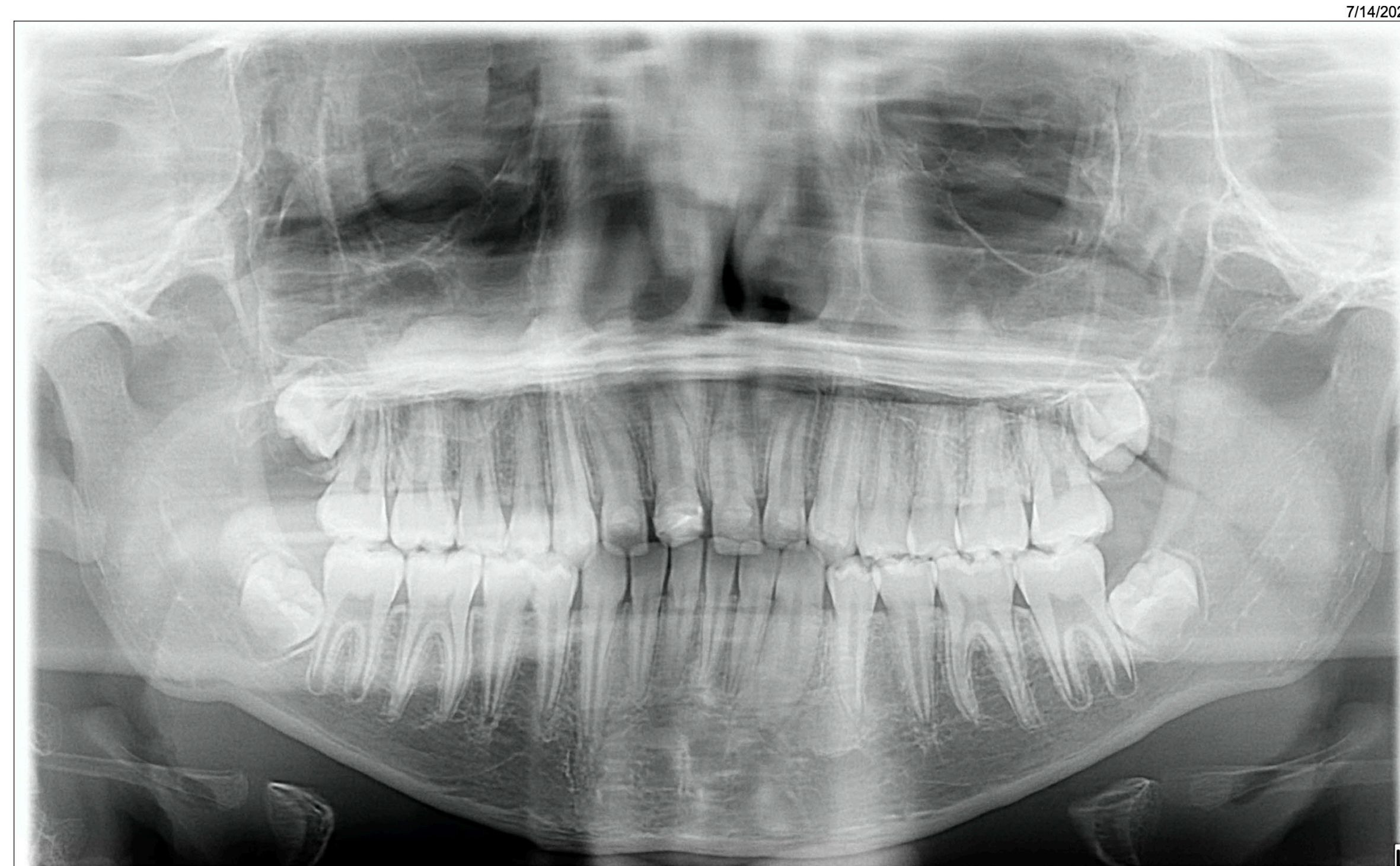### • Second tx visit

Root canal Therapy #8, 6 Month Radiograph #9

### • Third Visit

Crown #8,

## Panoramic radiograph



## Case Significance

Complicated crown fractures are defined as **fractures involving enamel and dentin with pulp exposure**. These injuries produce changes in the exposed pulp tissues, and a biological and functional restoration represents an important clinical challenge.

- dentists to play an active role in educating the public in the use of protective equipment for the prevention of orofacial injuries during sporting and recreational activities.
- dentists of all specialties, including pediatric and general dentists, to provide education to parents and patients regarding prevention of orofacial injuries as part of the anticipatory guidance discussed during dental visits.